

HYPERLIPIDEMIC ACUTE PANCREATITIS: A CASE-BASED REVIEW

Ivan Novakov

Department of Special Surgery, Medical University Plovdiv, 4000, Bulgaria, Plovdiv, "Vasil Aprilov" str. 15; inovakov2003@yahoo.com ; +359887575487

ABSTRACT

Hypertriglyceridemia is a rare cause of acute pancreatitis (accounts for about 1–7% of all cases of acute pancreatitis in large series). The aim of this publication is to discuss the incidence of hypertriglyceridemia-induced pancreatitis, using a case-based approach.

A case of 33-year-old woman with hyperlipidemic acute pancreatitis is presented. The woman was hospitalized due to severe abdominal pain, epigastric tenderness, biochemical and abdominal sonographic evidences of acute pancreatitis. There was no history of alcohol consumption and biliary disease. The past medical history established hyperlipidemia, treated with diet alone, and diabetes mellitus-type II. Subsequent laboratory investigation revealed marked hypertriglyceridemia. Emergent laparotomy was performed with severe necrotizing pancreatitis as an operative finding. Postoperative treatment was conducted in the intensive care unit. The woman died at the 3th postoperative day.

In a case-based approach we present the proposed mechanisms and the severity of hyperlipidemic acute pancreatitis.

key words: acute pancreatitis, hypertriglyceridemia

INTRODUCTION

Acute pancreatitis represents a serious clinical issue in every day surgical practice. Alcohol and gallstones are the most frequent etiologies of this potentially severe condition [1, 2, 3]. Other causes, like metabolic, structural and iatrogenic, account for up to 25% of acute pancreatitis cases.

L. Speck was the first (in 1865) who described an association of the hyperlipidemia and acute pancreatitis [4, 5, 6]. However, since then etiological correlation of lipid disorders and acute pancreatitis still remains unclear. Hyperlipidemia may be an epiphenomenon to acute pancreatitis - secondary lipid abnormalities are commonly found in patients with alcohol-induced acute pancreatitis and diabetic, pregnant and obese patients. Nevertheless, primary lipid disorders, especially hypertriglyceridemia may independently induce acute pancreatitis (responsible for up to 7% of cases) [3, 4, 5, 6, 7]. The aim of this manuscript is to discuss the incidence of hypertriglyceridemia-induced pancreatitis, using a case-based approach. The proposed mechanisms and the severity of hypertriglyceridemic acute pancreatitis are also discussed.

CASE PRESENTATION

A 33-year-old woman was admitted in our department of "Thoracic and Abdominal Surgery" (University Hospital "St. George" – Plovdiv), with symptoms of severe abdominal pain, nausea and vomiting, that occurred several hours before admission. There was no history of alcohol consumption and biliary disease. The past medical history established hyperlipidemia, treated with diet alone, and diabetes mellitus-type II.

Physical examination readings were as follows:

Body temperature - 39.5°C, Pulse - 110 beats per minute, Blood pressure - 90/60 mm of Hg, Respiratory rate - 21 breaths per minute. Her abdomen was rigid with rebound tenderness to palpation.

Results of laboratory and imagine evaluation were as follows:

Initial laboratory tests showed: lipemic serum, serum amylase 680 IU/l, serum lipase 1328 IU/l, C-reactive protein 251 mg/l, cholesterol 13.0 mmol/l, triglycerides 37.7/l, total bilirubin 81.4 μ mmol/l, urea 16.3 mmol/l, creatinine 126.0 μ mmol/l, glucose 12.3 mmol/l, lactate dehydrogenase 2003 IU/l, aspartate aminotransferase 113 IU/l, white blood cell count 16.6×10^9 /l. Urine level of amylase was 296 IU/l. Arterial blood gas analysis showed: pH 7.425, PaO₂ 54.1 mmHg and PaCO₂ 28.4 mmHg.

The abdominal ultrasound evaluation revealed: a swollen pancreas with heterogeneous structure, peripancreatic and intraperitoneal fluid collection. Thoraco-abdominal radiography (in lateral position) showed intraperitoneal free air (just below the anterior abdominal wall) / (fig. 1).

Figure 1.

Treatment and outcome

Emergent medial laparotomy was performed. Serous-hemorrhagic peritoneal effusion (in amount of 2000 ml), pancreatic necrosis (with necrosis of peripancreatic fat) / (fig. 2), and milky appearance (salmon-colored) of the stomach were established (fig. 3). Necrosectomy with removing of necrotic tissue of the body and tail of the pancreas, drainage of the peripancreatic space and the peritoneal cavity were established. Postoperative treatment was conducted in the intensive care unit. The woman died at the 3th postoperative day.

Figure 2.

Figure 3.

DISCUSSION

It is well known that hypertriglyceridemia is associated with acute pancreatitis, both as a cause (precipitant) and as an associated epiphenomenon [6, 7, 8]. Despite clear correlation, it is still difficult to differentiate if hypertriglyceridemia is a secondary comorbidity or a cause of acute pancreatitis. As reported in the literature, mild to moderate elevation in triglycerides (2-10 mmol/L) is accepted as a epiphenomenon in the early phase of acute pancreatitis, especially in alcohol-induced [5, 6, 7, 8]. Severe hypertriglyceridemia (serum levels more than 20 mmol/l) is a rare but well-documented cause of acute pancreatitis, establishing in experimental and clinical researches. "Hyperlipidemic pancreatitis" are cases of acute pancreatitis with presence of severe hypertriglyceridemia and absence of other causes, just like in the presenting case [7, 8, 9, 10].

The exact mechanisms involved in hypertriglyceridemia-induced pancreatitis are unclear. Chylomicrons are triglyceride-rich lipoprotein particles believed to be responsible for pancreatic inflammation [3, 4, 5]. These largest lipoproteins might impair circulatory flow in capillary beds. If this occurs in the pancreas, the resulting ischemia can disturb the acinar structure and expose these triglyceride-rich particles to pancreatic lipase. The pro-inflammatory non-esterified free fatty acids, generated from the enzymatic degradation of chylomicron-triglycerides, cause activation of trypsinogen and initiate acute pancreatitis [3, 4, 5, 6].

The clinical features of acute pancreatitis secondary to hypertriglyceridemia are no different from pancreatitis of other causes [1, 2, 9, 10]. Studies on patients with hypertriglyceridemia-induced pancreatitis have shown that extreme elevations of triglycerides

may induce severe abdominal pain - a state called “hyperlipidemic abdominal crisis”, that was the leading symptom in the presenting case [3, 4, 5, 6, 7, 8].

The diagnostic hallmark of AP is elevated amylase and/or lipase. Several studies have established that serum and urinary amylase levels are spuriously low in patients with hypertriglyceridemia-induced pancreatitis [9]. This has been attributed to an interference of plasma lipids with the assay or to the presence of an inhibitor in the plasma and urine that inhibits the assay. The common scenarios in which a clinician would encounter a patient with hypertriglyceridemia-induced pancreatitis include a poorly controlled diabetic with or without a history of hypertriglyceridemia, who have a lactescent serum [4, 5, 6, 7]. Lipemic (lactescent) serum is the strongest clue to hypertriglyceridemia-induced acute pancreatitis, just like in the presenting case.

In state of experimen, it was established that hypertriglyceridemia deteriorates the course of acute pancreatitis [4]. In human population it is still uncertain whether hypertriglyceridemia influences the evolution and outcome of pancreatitis. In the available literature, it has been suggested that the presence of hypertriglyceridemia is associated with more severe forms of acute pancreatitis and, controversially, that it does not intensify the course of this disease [7, 8, 9, 10, 11, 12]. The case that we presented supports the attitude that hypertriglyceridemia has influences on the severity and deteriorates necrotizing acute pancreatitis. Our patient has met the Ranson’s criteria (score ≥ 3 : WBC $>16 \times 10^9/l$, lactate dehydrogenase level >350 IU/l, aspartate aminotransferase >250 IU/l), as well as Atlanta’s local criteria (pancreatic necrosis) for severe acute pancreatitis, with death as an outcome.

CONCLUSION

In conclusion, on a case-based approach, severe hypertriglyceridemia was presented as a cause (precipitant) of acute pancreatitis. The proposed mechanisms, clinical presentation, and diagnosis of hypertriglyceridemia-induced acute pancreatitis were discussed. Finally, the presenting case supported the attitude that hypertriglyceridemia has influences on the severity and deteriorates acute pancreatitis.

REFERENCES:

1. Bollen TL, Van Santvoort HC, Besselink MG et al. The Atlanta Classification of acute pancreatitis revisited. *Br J Surg* 2008; 95:6–21.
2. Malfertheiner P, Kemmer TP. Clinical picture and diagnosis of acute pancreatitis. *Hepatogastroenterology* 1991; 38:97–100.
3. Radojković M, Stojanović M, Radojković D. et al. hyperlipidemia in acute pancreatitis: concomitant disorder or a cause? *Facta Universitatis Series: Medicine and Biology* 2014; 16:57–60.
4. Hu G, Zhao Y, Tang Y, Wang Y, Shen J, et al. Development of a novel model of hypertriglyceridemic acute pancreatitis in hamsters: protective effects of probucol. *Pancreas* 2012; 41:845–8.
5. Gan SI, Edwards AL, Symonds CJ, Beck PL. Hypertriglyceridemia- induced pancreatitis: a case-based review. *World J Gastroenterol* 2006; 12:7197–7202.
6. Baranyai T, Terzin V, Vajda A, Wittmann T, Czako L. Hypertriglyceridemia causes more severe course of acute pancreatitis. *Clin Lipidol* 2012; 7:731–736.
7. Yadav D, Pitchumoni CS. Issues in hyperlipidemic pancreatitis. *J Clin Gastroenterol* 2003; 36:54–62.

8. Oh RC, Lanier JB. Management of hypertriglyceridemia. *Am Fam Physician* 2007; 75:1365–1371.
9. Balachandra S, Virlos IT, King NK, Siriwardana HP, France MW, Siriwardena AK. Hyperlipidaemia and outcome in acute pancreatitis. *Int J Clin Pract* 2006; 60:156–159.
10. Joong HB, Sang HB, Ho SC, et al. Acute pancreatitis due to hypertriglyceridemia: report of 2 cases. *Korean J Gastroenterol* 2005; 46:475–480.
11. Deng LH, Xue P, Xia Q, Yang XN, Wan MH. Effect of admission hypertriglyceridemia on the episodes of severe acute pancreatitis. *World J Gastroenterol* 2008; 14: 4558–61.
12. Kyriakidis AV, Raitsiou B, Sakagianni A. et al. Management of acute severe hyperlipidemic pancreatitis. *Digestion* 2006; 73:259–64.

LEGENDS TO FIGURES:

Figure 1. Abdominal radiography (in lateral position) with intraperitoneal free air (just below the anterior abdominal wall).

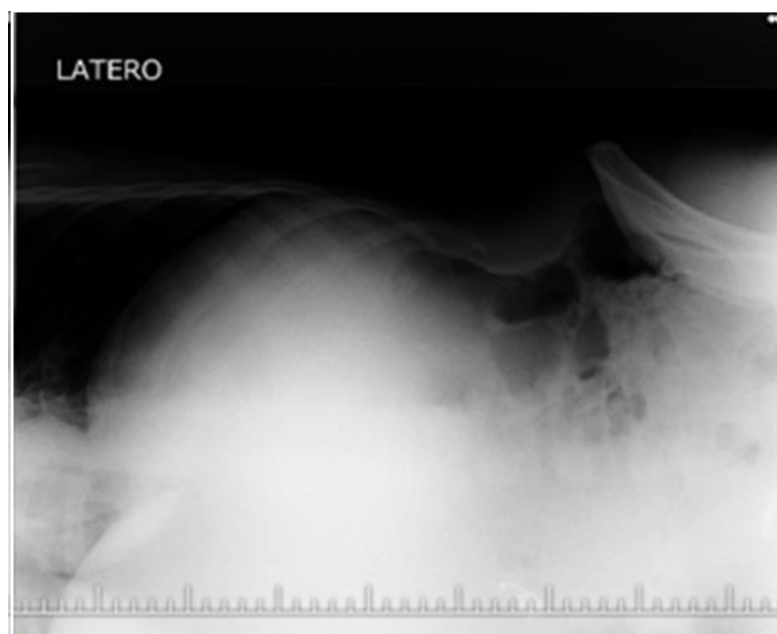


Figure 2. Operative finding: necrosis of the pancreas and peripancreatic fat.

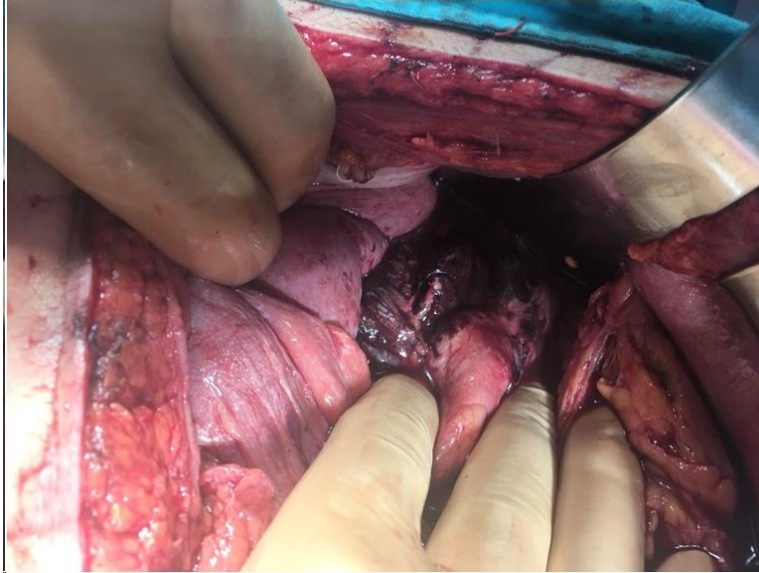


Figure 3. Operative finding: milky appearance (salmon-colored) of the stomach.

