

## BIO-TRACE ANALYSIS OF A BITE MARK SCAR LEFT ON THE HAND OF A PERPETRATOR OF A CRIME – A FORENSIC CASE REPORT

Atanas Christov, Teodora Kiryakova, Metodi Goshev, Biliana Mileva, Martin Angelov, Alexander Apostolov, Alexandar Alexandrov

*Department of Forensic Medicine and Deontology, Medical University-Sofia*

### ABSTRACT:

Introduction: We present a case of a homicide of a woman that was manually strangled after she was sexually abused. On the right hand of the suspect specific scars were observed that could be dated around a month before our examination. In addition we were given gypsum casts of the deceased's upper and lower jaws, as well as all the autopsy findings. Materials and methods: Examination of the suspect, analysis of the autopsy findings and the gypsum casts from the upper and lower jaws of the deceased, photo-superimposition, analysis of the results. Results: In this case, the obtained results showed the stable characteristics after the static and dynamic impact on perceptive surface (the hand of the perpetrator). These characteristics of the scars perfectly matched the specific features of the gypsum casts from the upper and lower jaw of the deceased. The study was performed by photo-superimposition and bio-trace analysis. Conclusion: Such types of forensic analysis are extremely important and informative in investigating criminal offenses, especially in cases where there is no other objective evidence (material evidence, testimony, available DNA research material, etc.) to identify the perpetrator of the crime

**Key words:** *bite mark scar, bio-trace analysis, forensic medicine*

### INTRODUCTION

Forensic trace analysis is a section of forensic medicine that develops methods for determining group belonging and identifying objects based on the characteristics of their traces on injured tissues [1,2]. Bio-trace analysis for its part, is a study that first examines traces left on human tissues [3], then analyzes experimental damage done with the alleged traumatic agent, and ultimately compares both types of traces, making a final analysis and evaluation of the results [4,5]. One of the most appropriate methods in the case of action of blunt objects is that of imposing and sliding [5,6].

### PRESENTATION OF A CLINICAL CASE

This is a case of a homicide of a woman, who was manually strangled after being sexually assaulted. There were no witnesses of the crime. Due to that fact, within a month, the law enforcement authorities gradually limited the investigation to several suspects, all of whom were questioned and subjected to primary physical examinations. During those, on the right hand of one of the detainees, an uncommon complex of injuries was observed, which required additional forensic medical examination.

During the forensic study it was found that, on the back surface of the right hand, in the area of the projection of the second metacarpal bone, three scars were observed, forming a configuration of a generally arcuate shape. They were pinkish-whitish, located at the level of the surrounding skin, with fallen off crust, which dated them to approximately one month old to the time of the examination. The morphology of the detected scars indicates that they are the result of a healing process of superficial wounds caused by the action of blunt objects with well-formed edges of the restricted contact surfaces, in a characteristic grouping and arrangement, with a pronounced combination of dynamic and static impact (Photo 1).

To further elucidate the origin of the scars and their possible connection to the crime, the doctors were given gypsum castings of the deceased woman's teeth rows, whose characteristics were as follows:

- Upper teeth row - the central incisors have a diameter of about 6 mm for each, with expressed crown abrasion that protrudes to 2-3 mm above the gum level. They have pointed, uneven cutting edges in their front parts, with a slight skew protrusion of the lateral cutting edge of the central right incisor. The rest of their crowns are abraded to the gum level. The crown of the upper left lateral incisor is abraded to the level of the gum. The crown of the upper right lateral incisor has a diameter of about 4 mm with a worn uneven chewing surface and a shaped tip at the cutting edge area about 5 mm back in the overall configuration of the tooth row, relative to the cutting edges of the central incisors. Teeth from the third to the seventh one on the left have heavily abraded broad chewing surfaces. The third upper left tooth has a relatively well-formed edge in its front and medial parts, located 7-8 mm from the cutting edge of the central left cutter and about 4 mm back in the overall configuration of the tooth row, relative to the cutting edges of the central incisors. The right fourth and seventh teeth are preserved, with relatively smooth, abraded chewing surfaces (Photos 2 and 3).

- Lower teeth row - the two central incisors, the right lateral incisor, the left lateral incisor and the left canine tooth are small, unevenly abraded, with a cutting edge width of 2-4 mm. The front edges of the teeth are strongly tapered, uneven, with protruding peaks. The backs of their crowns are erased to 1 mm from the gum level. The crowns of the third and fourth teeth on the right are about 5 mm wide, with tapered edges and abraded middle parts. The remaining teeth are missing, their alveoli are smooth (Photos 4 and 5).

Experimental traces were made with the gypsum casts in a combination of static-dynamic impact with a base for the trace-adoptive surface - polyurethane pad; trace-adoptive surface - white sheets of paper; trace-reflective material - indigo; trace-forming conditions - perpendicular pressure combined with a dynamic pulling component (varying pressure in the range of about 15 °, 30 °, 45 °, combined with a dynamic component). The analysis of the obtained results showed that, persistent repetitive components, consisting of the main contact elements of the three teeth with a slope of between 15° and 45°, were found (Photos 6 and 7). The trace analysis, performed by the comparison and sliding method, presented that the scars on the back of the suspect's right hand could be a result from healing of wounds, caused by the action of the deceased woman's upper teeth row (Photo 8).

## CONCLUSION

Such types of forensic analysis are extremely important and informative in investigating criminal offenses, especially in cases where there is no other objective evidence (material evidence, testimony, available DNA research material, etc.) to identify the perpetrator of the crime.

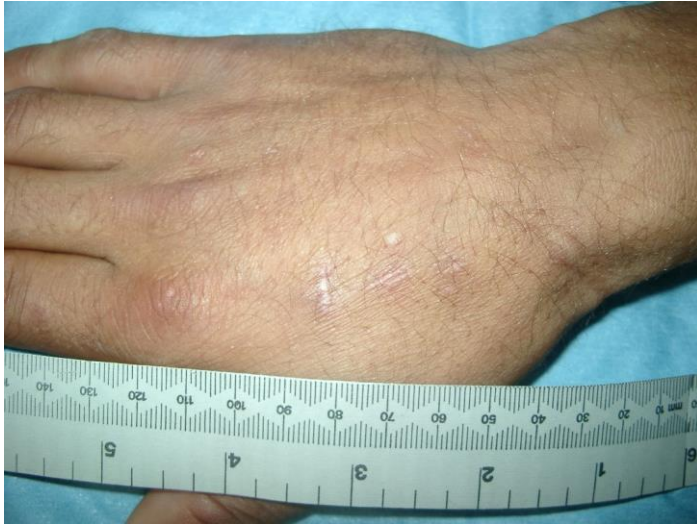Statement for Potential Conflicts of Interest – No potential conflict of interest was reported by the authors.

## REFERENCES

1. Spitz and Fisher: *Medicolegal investigation of death*. Fourth edition, Illinois: Charles C Thomas Publisher, LTD, 2006;
2. Раданов С.: *Съдебна медицина и медицинска деонтология*. Трето основно и допълнено издание, С. изд. Сиела, 2006;
3. Siegel, J. A. (Ed.): *Encyclopedia of forensic sciences* (3 volumes). London: Academic Press, 2000;

## Science & Research

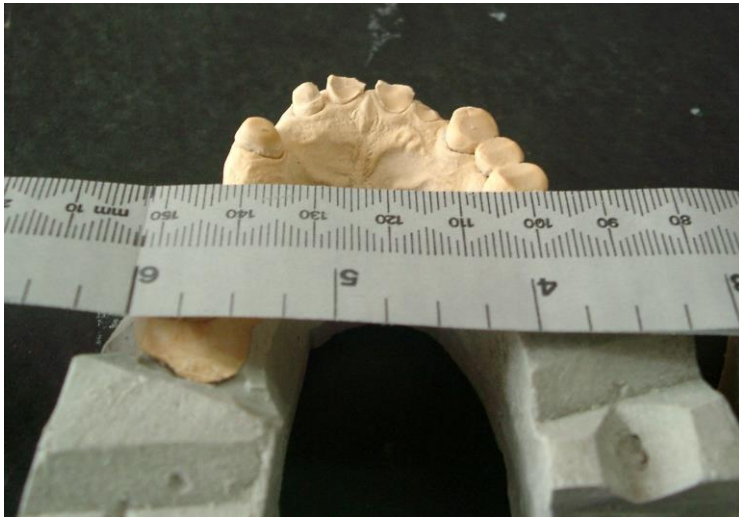4. Хазиев Ш.Н. Техничко-криминалистические методы установления признаков неизвестного преступника по его следам: Учебное пособие. – М.: Академия МВД СССР, 1986. – 40.;
5. Христов, Ст., Апостолов, А. Случай на идентификация на извършителя при наличие на динамични и статични следи от съзъбие по тялото на пострадалата. Списание по съдебна медицина и криминалистика. С. 2002 (107-108): 149 - 153.
6. Anonymous. Body identification guidelines. American Board of Forensic Odontology, Inc. J Am Dent Assoc 1994;125(9):1244–6,1248,1250.



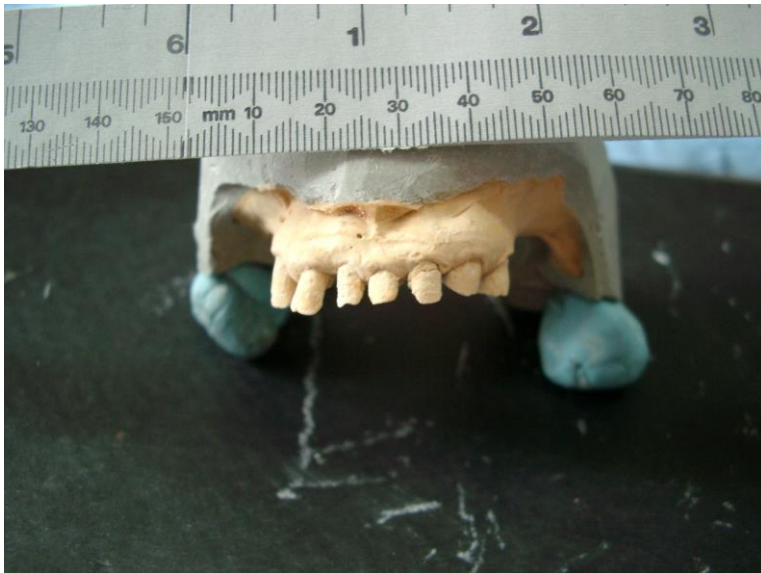**Photo 1**



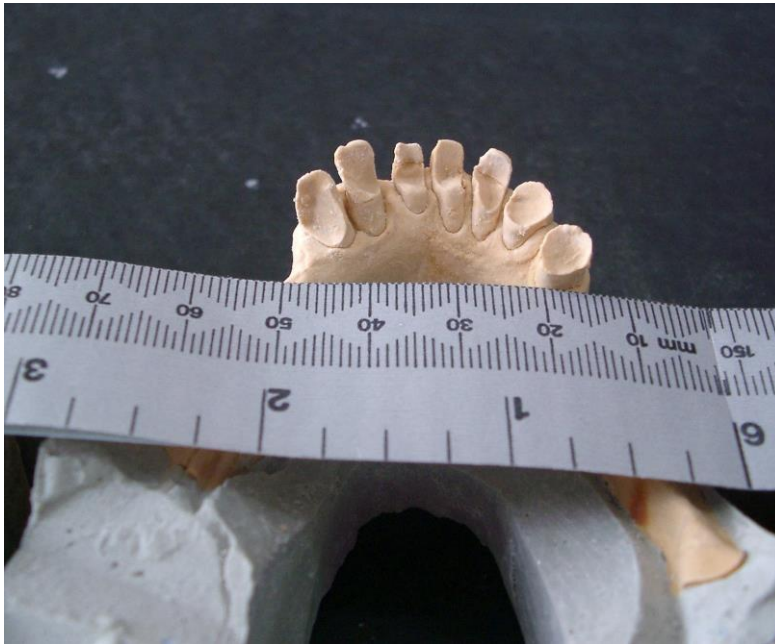**Photo 2**




**Photo 3**



**Photo 4**




**Photo 5**

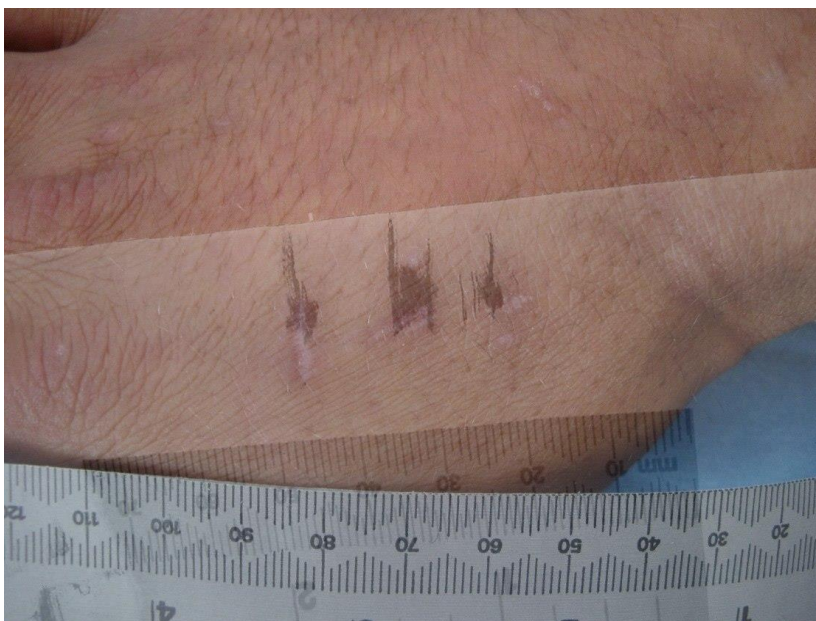

**Photo 6**





**Photo 7**



**Photo 8**

*Corresponding author: Atanas N. Christov, MD, Medical University, Sofia-1431, Bulgaria Department of Forensic Medicine and Deontology 2 Zdrave Str. Tel: +359+29230749 Fax: +359+29230412 E-mail: [iamnasko@yahoo.com](mailto:iamnasko@yahoo.com)*